



PRESENTING CLINICAL SIGNS

DATE History: Experienced first episode of CHF in 2018. Currently receiving furosemide 6.25 mg am and 12.5 mg pm, pimobendan 1.25 mg BID, and spironolactone 6.25 mg SID. Doing well.

8/15/22

ECHOCARDIOGRAPHIC FINDINGS

2D, M-mode, and Doppler study.

PERFORMED BY:

Dr. Meredith Swart

INTERPRETED BY

Keith Blass, DVM,
MS, DACVIM
(Cardiology)

There is moderate left atrial dilation. The mitral valve leaflets are thickened and exhibit systolic prolapse. There is Doppler evidence of mitral regurgitation present. There is mild to moderate left ventricular dilation. Left ventricular systolic function is hyperdynamic. The aorta and aortic valve are normal. Right atrial and right ventricular dimensions are normal. The tricuspid valve appears normal, though trace tricuspid regurgitation is present. The pulmonary artery and pulmonic valve are normal. No shunting lesions are visualized. No pericardial effusion or cardiac masses are seen.

LA - 30.8 mm
LVIDd - 27.2 mm
LVIDs - 13.6 mm
FS - 50%
RA - 14.3 mm
LVOT - 1.08 m/s
RVOT - 0.76 m/s

PATIENT

Chico Woods

SPECIES

Canine

ASSESSMENT/RECOMMENDATIONS

Degenerative mitral valve disease

BREED

Chihuahua

This examination demonstrates regurgitation of blood across Chico's mitral valve resulting from his previously diagnosed degenerative valve disease. Secondary to his regurgitation, Chico has moderate dilation of his left atrium and mild to moderate dilation of his left ventricle. Chico's mitral valve disease is currently compensated, however, the presence of moderate left atrial dilation indicates that he is at risk for the recurrence of congestive heart failure, as well as other clinical signs of cardiac dysfunction, such as coughing, exercise intolerance, and syncope.

SEX

No change therapy is recommended based on this exam.

MN

A recheck echocardiogram is recommended in 9-12 months. Thoracic radiographs are recommended if Chico experiences respiratory clinical signs.

AGE

15 y

WEIGHT

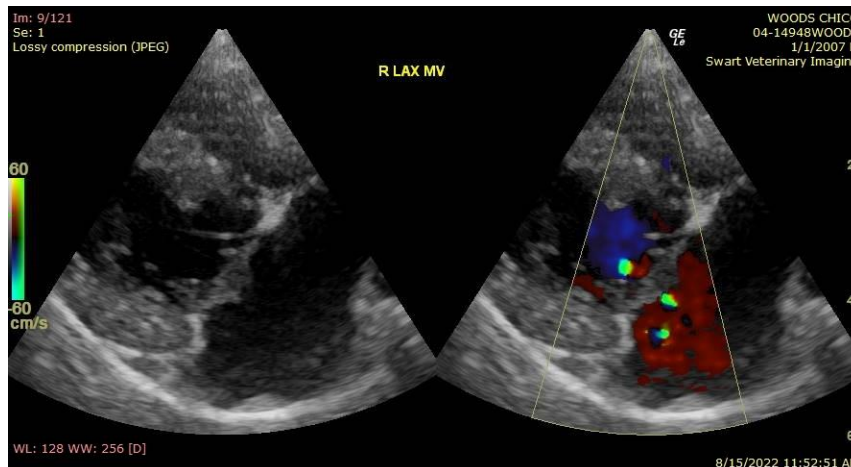
6.3 lb

HOSPITAL NAME

Swart Veterinary
Imaging

REFERRING VET

Dr. Swart





DATE

8/15/22

The information and recommendations provided are based on the images presented by the referring veterinarian. No evaluation can be communicated regarding pathology that was not visible in the image/video clips provided.

PERFORMED BY:

Dr. Meredith Swart

Thank you for this referral. If the clinical or image interpretation does not parallel your findings or if I can be of any further assistance please contact me.

INTERPRETED BY

Keith Blass, DVM, MS, DACVIM (Cardiology)
KeithBlass@gmail.com
631-804-5754

Keith Blass, DVM,
MS, DACVIM
(Cardiology)

PATIENT

Chico Woods

SPECIES

Canine

BREED

Chihuahua

SEX

MN

AGE

15 y

WEIGHT

6.3 lb

HOSPITAL NAME

Swart Veterinary
Imaging

REFERRING VET

Dr. Swart